

Comparison of Ultrasound-guided Costoclavicular Block versus Axillary Block for Below Elbow Surgery: A Randomised Clinical Study

BN CHAITHRASHREE¹, SURBHI GUPTA², THOMAS T VELLAPALLY³

ABSTRACT

Introduction: Ultrasound-guided brachial plexus blocks are widely used to provide anaesthesia for upper limb surgery. Costoclavicular Block (CCB) is a newer infraclavicular approach to brachial plexus block where local anaesthetic is deposited between the midpoint of the clavicle and the first rib.

Aim: To compare the efficacy of ultrasound-guided CCB to Axillary Block (AXB) for below elbow surgery.

Materials and Methods: This randomised clinical study included 70 patients belonging to ASA I and II category, aged between 18 and 59 years undergoing below elbow surgery. Patients were randomly allocated to either CCB group or AXB group under ultrasound guidance using 20 mL of local anaesthetic mixture (10 mL of 0.5% bupivacaine and 10 mL of 2% lidocaine with adrenaline). Sensorimotor block onset time, block performance time, total anaesthesia-related time, success rate and complications were recorded. Independent t-test was used to determine significance between two

quantitative variables and Fischer's-exact test was used as test of significance for qualitative data.

Results: Both groups were comparable in terms of demographic data (age, sex, body mass index and American Society of Anaesthesiologists (ASA) grading) with a p-value of >0.05. The mean (SD) sensorimotor onset time was similar between the CCB and AXB groups (14.71±1.18 vs 14.85±2.33 minutes), respectively; p-value=0.764. Mean block performance time was shorter in CCB than AXB group (5.83±0.82 vs 8.74±0.85 minutes) respectively; p-value <0.001. CCB group had a shorter total anaesthesia-related time compared to AXB group (20.69±0.87 vs 23.79±2.19 minutes) respectively. Success rate was similar between costoclavicular and axillary approaches. No complications were noted in either group.

Conclusion: Though the onset time and success rate were similar between the two groups, CCB resulted in a shorter performance time and total anaesthesia-related time. Thus, CCB is a safe and reliable alternative to AXB for below elbow surgery.

Keywords: Brachial plexus block, Bupivacaine, Lignocaine, Local anaesthetics, Regional anaesthesia

INTRODUCTION

Ultrasound-guided peripheral nerve blocks are an essential armamentarium of the anaesthesiologist. Brachial plexus blocks are widely used to provide anaesthesia for upper limb surgeries [1]. Various approaches are used for performing brachial plexus blocks like interscalene, supraclavicular, infraclavicular and axillary, each having its own advantages and disadvantages [2].

For elbow, forearm, and hand surgeries, AXB is a commonly utilised peripheral nerve block [3]. The radial, median, and ulnar nerves are located near the axillary artery and appear as hyperechoic structures surrounding the axillary artery on ultrasonography. The musculocutaneous nerve lies between the biceps and coracobrachialis muscles outside the axillary sheath. More than one injection is required for depositing local anaesthetic around the axillary artery to block the median, radial and ulnar nerves and a separate injection is needed for anaesthetising the musculocutaneous nerve in between the coracobrachialis and biceps muscle [4].

The CCB is a variation of infraclavicular block that was first described considerably later than the AXB for elbow, forearm, and hand procedures [5]. Anatomically, the Costoclavicular Space (CCS) is located between the subclavius and serratus anterior muscles that cover the first rib and behind and deep to the middle of the clavicle [6]. The brachial plexus cords are grouped lateral to the axillary artery at the CCS, and they have a regular anatomical relationship with one another and the axillary artery [7]. The three cords can be seen in a single ultrasound window and can be blocked with a single injection

of local anaesthetic in the CCS [8]. The technique has decreased puncture-related problems and enhanced the safety and speed of the brachial plexus block [9]. Various studies [2,3,10] have been done to compare the different approaches to the brachial plexus but there are very few studies [11-13] which have compared the newer CCB to the already established approaches to the brachial plexus block.

Thus, this randomised study was done to compare ultrasound-guided CCB with ultrasound-guided AXB in patients undergoing below elbow surgery. Our primary objective was to compare the onset of sensory and motor block. Our secondary objectives were to compare the block performance time, total anaesthesia related time, success rate and occurrence of complications like vascular puncture, haemorrhage, pneumothorax and local anaesthesia toxicity in both the groups.

MATERIALS AND METHODS

This randomised parallel group clinical study was conducted at St John's Medical College, Bangalore, Karnataka, India, between December 2020 and December 2022. Ethical clearance was obtained from the institutional ethics committee (Ref no 392/2020) and the study was listed with the Clinical Trials Registry of India (CTRI/2021/11/038097). Written informed consent was obtained from each participant.

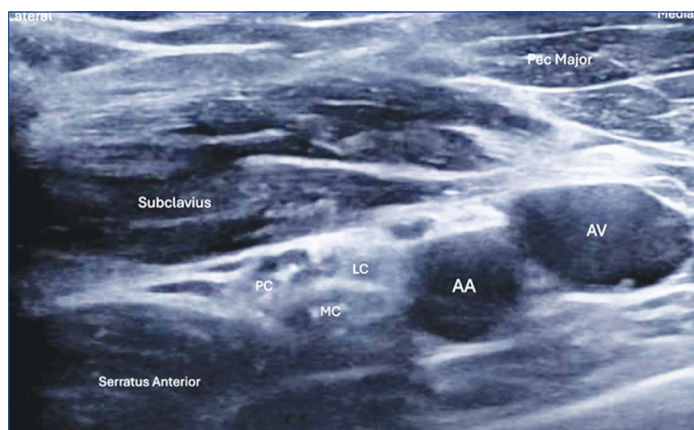
Inclusion criteria: Patients aged between 18 and 59 belonging to ASA physical status I and II who underwent elective or emergency below-elbow surgery.

Exclusion criteria: Patients with a history of hypersensitivity to local anaesthetic drugs, pregnant and lactating women, skin infection at the site of needle insertion, coagulopathy, patients with pre-existing neurological disorders.

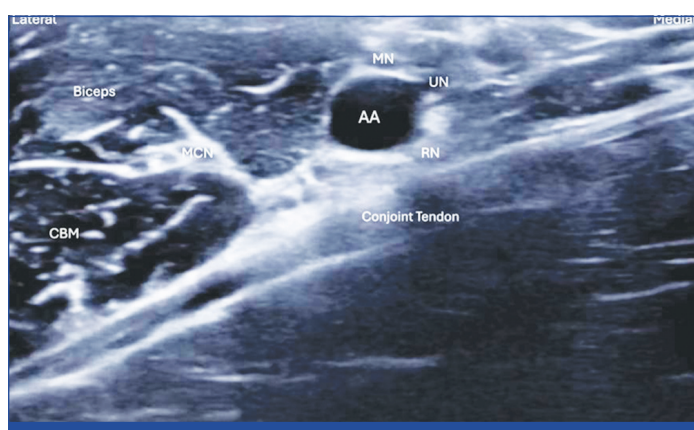
Sample size selection: Based on available literature [5,14] at the time of initiation of study, a sample size of 35 patients was needed in each group to detect a 7-minute difference in the onset time for motor block between USG guided CCB and AXB. This was considering an average standard variation of six minutes, with 5% level of significance and 80% power. This sample size was also adequate to observe a mean difference of five minutes in sensory block between the study arms.

Study Procedure

A total of 70 patients were assessed for their eligibility to participate in the study. A computer-generated sequence was used to randomly assign patients into two groups. Group CCB (n=35) received an ultrasound-guided CCB [Table/Fig-1], while Group AXB (n=35) received an ultrasound-guided AXB [Table/Fig-2]. Opaque sealed envelopes were prepared for allocation concealment. These were opened just before the block by the anaesthesiologist who was going to perform the procedure. The same person assessed the block intraoperatively and followed up the patient postoperatively. The Consolidated Standards of Reporting Trials (CONSORT) diagram is presented in [Table/Fig-3].

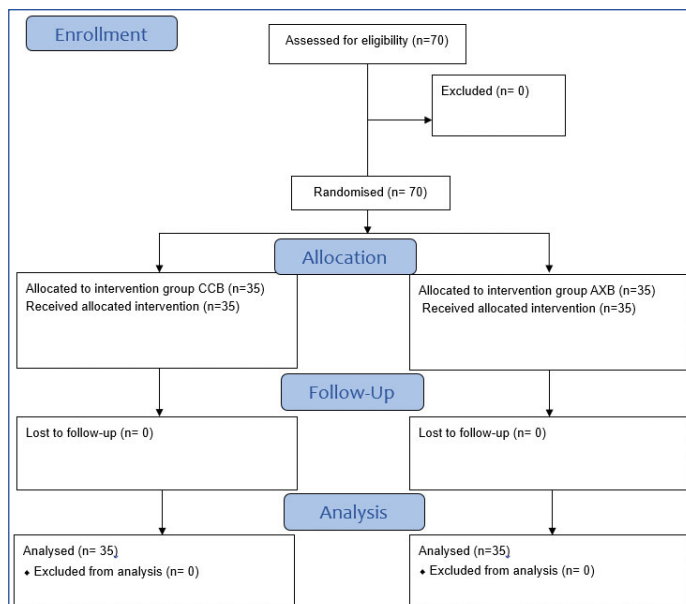


[Table/Fig-1]: Ultrasound image for Costoclavicular Block (CCB). AA: Axillary artery; AV: Axillary vein; PC: Posterior cord; LC: Lateral cord; MC: Medial cord.



[Table/Fig-2]: Ultrasound image for Axillary Block (AXB). AA: Axillary artery; MN: Median nerve; UN: Ulnar nerve; RN: Radial nerve; MCN: Musculocutaneous nerve; CBM: Coracobrachialis muscle

A detailed pre-anaesthetic evaluation was done prior to surgery and written informed consent was taken. After confirming fasting status patients were shifted to the Operation Room (OR). In the contralateral upper limb, a peripheral venous access (20 G) was established. Standard ASA monitors were attached, including an electrocardiogram, pulse oximeter and non-invasive blood pressure. Patients in both the groups were premedicated using 0.02 mg/kg midazolam i.v.. All the blocks were performed by an experienced anaesthesiologist using



[Table/Fig-3]: CONSORT diagram.

high frequency linear USG probe (6-13 MHz sonosite) with a nerve block needle under strict aseptic precautions. Both groups received 20 mL volume of local anaesthetic mixture, which consisted of 10 mL of 0.5% bupivacaine and 10 mL of 2% lidocaine with adrenaline [15-17].

Patients in the CCB group were put in a supine position with their head slightly rotated to the opposite side and their operative limb in a 90-degree abduction. Under all aseptic conditions, USG probe was placed on the middle third of the clavicle and anatomical landmarks were identified. Subsequently, the axillary artery and vein were identified by translocating the probe caudally to the infraclavicular fossa. To visualise the CCS beneath the subclavius muscle, the transducer was angled cephalad. Lateral to the axillary artery, the three brachial plexus cords were visualised [Table/Fig-1]. After infiltrating skin with 2% lignocaine, the needle was passed from lateral to medial direction in an in-plane technique and 20 mL of local anaesthetic was injected at the centre of the nerve cluster after negative aspiration for blood.

Patients in the AXB group were put in a supine position with their elbows flexed and their arms abducted. An USG probe was placed in the axilla to view the axillary artery following appropriate aseptis. Around the axillary artery, the median, ulnar, and radial nerves were identified and the musculocutaneous nerve between the biceps and coracobrachialis was visualised [Table/Fig-2]. After infiltrating skin with 2% lignocaine, the needle was passed twice in an in-plane technique initially from anterior to posterior aspect of the axillary artery where 5mL of anaesthetic was deposited around each of the median, ulnar, radial nerves. Remaining 5mL of local anaesthetic was deposited around musculocutaneous nerve.

Onset time of the sensorimotor block was recorded. The lateral side of the forearm, the thumb's volar aspect, lateral aspect of the dorsum of the hand and volar aspect of the fifth finger were used to assess sensory blockage of the musculocutaneous, median, radial, and ulnar nerves, respectively. The pin prick test was used to grade sensory blockage on a three-point scale. {0=nil block; 1=analgesia (patient can perceive touch, not pin prick); 2=anaesthesia (patient cannot perceive touch)}. The total sensory score out of eight was recorded at different intervals of time.

Elbow flexion, thumb abduction, thumb opposition, and thumb adduction were used to assess motor blockage of the musculocutaneous, radial, median, and ulnar nerves, respectively. A three-point rating system was also used to grade motor blockade. (0=no block; 1=paresis; 2=paralysis). The total motor score out of 8 was recorded at different intervals of time.

The composite sensorimotor score (sum of sensory and motor score) out of 16 points was also noted. The patient was considered ready

for surgery if they had a minimum composite score of 14 points with a minimum sensory block score of ≥ 7 out of 8. The block onset time was defined as the time needed to achieve ≥ 14 points following the end of the local anaesthetic mixture injection [12,18,19].

The assessment of the sensory and motor block at five minutes interval in the first half hour was recorded. Supplementation of local anaesthetics or rescue nerve block, conversion to general anaesthesia was considered as unsuccessful block. Block performance time (duration between local infiltration of skin and end of local anaesthetic injection through the needle), total anaesthesia-related time (aggregate of performance time and onset time), complications such as vascular puncture, local anaesthetic systemic toxicity, nerve injury, allergic reactions were recorded.

STATISTICAL ANALYSIS

The Statistical Package for Social Sciences (SPSS) version 27 was used to analyse the obtained data. Descriptive statistics were reported using frequencies and proportions for the categorical data and mean with SD for the continuous data. Chi-square test or Fischer’s-exact test was employed to test the statistical significance of categorical data. Independent t-test was used to determine significance between quantitative variables. Statistical significance was defined as a p-value of less than 0.05.

RESULTS

Demographic data was comparable between the two groups [Table/Fig-4].

Variables	CCB group	AXB group	p-value
Age (years)	32.97±10.93	34.71±10.67	0.502
Sex (male: female)	21:14	21:14	1
BMI	23.3±2.58	23.15±1.79	0.789
ASA (I: II)	23:12	22:13	0.803

[Table/Fig-4]: Demographic variables.
Reported as number (%); p-value using Fisher’s-exact test; p <0.05* statistically significant; p<0.001** statistically highly significant.

[Table/Fig-5] shows the number and percentage of patients who achieved a total sensory block score ≥ 7 at different intervals of time, while [Table/Fig-6] depicts the number and percentage of patients with total motor block score ≥ 7 achieved in both the groups. [Table/Fig-7] compares the number and percentage of patients who achieved a total composite sensorimotor block score ≥ 14 at different intervals of time in both the groups.

Time elapsed after performing the block	Number of patients with sensory block score ≥ 7		p-value
	CCB group	AXB group	
5 minutes	0	0	-
10 minutes	15 (42.9)	16 (45.7)	0.810
15 minutes	35 (100)	34 (97.1)	0.314
20 minutes	35 (100)	35 (100)	-
25 minutes	35 (100)	35 (100)	-
30 minutes	35 (100)	35 (100)	-

[Table/Fig-5]: Comparison of sensory block score ≥ 7 between study groups
Reported as number (%); p value using Fisher’s exact test; p<0.05* statistically significant; p<0.001** statistically highly significant

The onset time of sensorimotor block was similar in both the groups [Table/Fig-8]. Statistically significant difference was seen in the block performance time between the two groups (p<0.001), with CCB requiring shorter time to perform. Total anaesthesia-related time was significantly lesser in costoclavicular group compared to axillary group (p<0.001) [Table/Fig-8].

All patients in both the groups had a successful block for providing surgical anaesthesia. Hence, there was no significant

Time elapsed after performing the block	Number of patients with motor block score ≥ 7		p-value
	CCB group	AXB group	
5 minutes	0	0	-
10 minutes	5 (14.3)	4 (11.4)	0.721
15 minutes	35 (100)	32 (91.4)	0.077
20 minutes	35 (100)	35 (100)	-
25 minutes	35 (100)	35 (100)	-
30 minutes	35 (100)	35 (100)	-

[Table/Fig-6]: Comparison of motor block score ≥ 7 between study groups.
Reported as number (%); p value using Fisher’s exact test; p<0.05* statistically significant; p<0.001** statistically highly significant

Time elapsed after performing the block	Number of patients with composite sensorimotor block score ≥ 14		p-value
	CCB group	AXB group	
5 minutes	0	0	-
10 minutes	2 (5.7)	4 (11.4)	0.393
15 minutes	35 (100)	32 (91.4)	0.239
20 minutes	35 (100)	35 (100)	-
25 minutes	35 (100)	35 (100)	-
30 minutes	35 (100)	35(100)	-

[Table/Fig-7]: Comparison of composite sensorimotor block score ≥ 14 between study groups.
Reported as number (%); p-value using Fisher’s exact test; p<0.05* statistically significant; p<0.001** statistically highly significant

Parameters	CCB group (Mean±SD)	AXB group (Mean±SD)	p-value
Block onset time/Time to score ≥ 14 (minutes)	14.71±1.18	14.85±2.33	0.764
Block performance Time (minutes)	5.83±0.82	8.74±0.85	<0.001**
Total anaesthesia-related time (minutes)	20.69±0.87	23.79±2.19	<0.001**

[Table/Fig-8]: Comparison of various parameters-sensorimotor block onset time, block performance time and total anaesthesia related time.
p-value using independent t test; p<0.05* statistically significant; p<0.001** statistically highly significant

difference between the two groups in terms of successful block distribution. There were no complications like vascular puncture, haemorrhage, pneumothorax and local anaesthesia toxicity in either of the groups.

DISCUSSION

In the present study, we compared the block characteristics of ultrasound-guided CCB which is a newer approach to brachial plexus block as compared to the already established AXB. The CCS is a distinct intermuscular area that extends deep to the posterior midpoint of the clavicle. In the CCS, the medial, lateral, and posterior brachial plexus cords are compactly arranged under a single fascial compartment [5]. In axillary approach, the individual nerves have to be identified and then blocked using local anaesthetics.

A better understanding of sonoanatomy has enabled anaesthetists to reduce the dose of local anaesthesia drugs for nerve blocks in the recent years. We have used 20 mL volume of local anaesthetic mixture for performing the block, which consisted of 10 mL of 0.5% bupivacaine and 10 mL of 2% lidocaine with adrenaline. This dosage is supported by studies which have used 20 mL volume for different approaches of brachial plexus block under USG guidance and achieved successful outcomes [15-17].

We used a 16 point scoring method for assessing the onset of sensorimotor block. We found that the mean onset time of sensorimotor block was comparable in costoclavicular and axillary groups (14.71±1.18 minutes in CCB and 14.85±2.33 minutes in AXB (p=0.764). As the local anaesthetic was deposited near the three cords

in CCB and in close proximity to the individual nerves in AXB, the onset time was similar in both our groups despite using two separate local anaesthetic injections in AXB group. The result of the present study was similar to that of Nalini KB et al., who compared ultrasound-guided costoclavicular and axillary nerve block using 30 mL of local anaesthetic mixture of bupivacaine and lignocaine [12]. They demonstrated a similar onset time between the two groups. The block onset time was shorter in their study as compared to ours which could be because of the higher volume (30 mL) of local anaesthetic drug used in their study. Ramesh SM et al., compared CCB with supraclavicular block for forearm surgeries and concluded that the onset time was significantly lower in costoclavicular group (8.20 ± 0.58 minutes) compared to supraclavicular group (9.72 ± 0.84 minutes) [18].

Tran DQ et al., found a block onset time of 17.8 ± 6.9 minutes using 35 mL of 1.5% lignocaine with adrenaline and Yanli Y et al., reported a block onset time of 17.19 ± 2.71 minutes using a mixture of 35-mL of 1% lidocaine and 0.25% bupivacaine in ultrasound-guided AXB [20,21].

Li JW et al., and Songthamwat B et al., studied the effectiveness of ultrasound-guided CCB using 20-25 mL 0.5% ropivacaine in patients undergoing upper limb procedures [5,22]. The onset of block was much faster in their studies {5(5-15) minutes and 10(10-26.25)} minutes {median (interquartile range)} respectively vs. 14.71 ± 1.18 min in our study. Dost B et al., found that the sensory block onset time was 4 (3.88-6) minutes and the onset time of motor block was 5 (4-6.48) minutes in patients undergoing CCB using 20 mL of 0.5% bupivacaine which was much shorter than our study [23]. This difference between various studies could be due to variability in the type and volume of local anaesthetic used and the difference in how the block onset time was defined.

The present study showed that the mean performance time of the ultrasound-guided CCB (5.83 ± 0.82 minutes) was shorter than AXB (8.74 ± 0.85 minutes) $p < 0.001$. In CCB, the three cords have a consistent and compact arrangement lateral to the axillary artery where they can be visualised easily and be blocked by a single needle injection. In AXB there may be inter individual variability in the arrangement of the median, ulnar and radial nerves around the axillary artery necessitating variation in the needle direction for injecting local anaesthetic near these nerves. Also, as the musculocutaneous nerve was blocked by a separate needle pass, the total time of performing the AXB was greater than the CCB. This was similar to the study by Nalini KB et al., who found that the performance time was significantly shorter in CCB as compared to AXB [12].

A shorter performance time for the block will add to patient comfort and overall better experience for the patient in the operation theatre. A few studies have described the shorter performance time of CCB as compared to supraclavicular, infraclavicular and axillary approaches to the brachial plexus block due to the tightly packed and reliable anatomical placement of the three cords in the CCS [8,18]. However, Luo Q et al., compared CCB with interscalene block in shoulder arthroscopic surgeries and demonstrated a significantly shorter block performance time in interscalene approach (346.49 ± 108.60 seconds) in comparison with CCB (376.92 ± 113.37 seconds) [24].

Some studies defined performance time as the aggregate of scanning time and needling time [19,25,26]. Scanning time depends on the variability of nerve position and depth of nerves in the different approaches to brachial plexus block. Increase in scanning time and needling time both can increase the block performance time. Tran DQ et al., found that both the scanning and needling time was more in axillary as compared to supraclavicular and infraclavicular approaches [20]. As axillary approach requires extensive scanning to identify the individual nerves and injection around them, scanning and needling time both were higher in this approach. Even though we did not include the scanning time in our performance time the needling time in the axillary approach in our study was higher showing similarity to Tran DQ et al., study [20].

In this study total anaesthesia-related time in costoclavicular group was 20.69 ± 0.87 minutes and in axillary group was 23.79 ± 2.19 minutes. There was a statistically significant difference in mean total anaesthesia-related time between two groups, $p < 0.001$, as there was a significant difference in the performance time between the two groups while the mean onset time was similar in both the groups. Nalini KB et al., also concluded that the total anaesthetic time was significantly shorter in costoclavicular group compared to axillary group owing to the shorter block performance time in costoclavicular approach [12]. On the contrary, Song IA et al., and Tran DQ et al., observed that, though the performance time in AXB was longer, the total anaesthesia related time was similar to the other approaches of brachial plexus block as the onset time was faster in the axillary approach in their studies [2,20].

In the present study, there was no significant difference in success rate of the two groups (100% in CCB and 100% in AXB). Nalini KB et al., also demonstrated a similar success rate for both CCB and AXB groups [12].

In the AXB, several needle passes could increase the risk of vascular puncture. The costoclavicular technique may be more beneficial for patients with coagulation disorders than the axillary approach since the target point is situated lateral to the artery, between the three brachial plexus cords, as opposed to perivascularly with the axillary approach. In studies by Tran DQ et al., and Hussien R and Ibrahim D vascular puncture has been reported because of the close proximity of the nerves to the axillary artery [20,27]. However, none of our patients had any complications of vascular puncture or local anaesthetic toxicity in either AXB or CCB group.

Limitation(s)

This was not an observer blinded study; the person who noted the block characteristics was not blinded to the approach used for the brachial plexus block which could have led to bias in the results. Scanning time was not included in our study. Axillary approach necessitates identification of individual nerves which requires more extensive scanning. If the scanning time had been included in our study it may have further prolonged the performance time in axillary group.

CONCLUSION(S)

This randomised controlled study compared ultrasound-guided CCB with AXB for below elbow surgeries. The results demonstrated that CCB has a similar onset of sensorimotor block and success rate when compared to AXB. However, the costoclavicular approach has a shorter block performance time thereby decreasing the total anaesthesia-related time. No complications were observed in both the groups. Thus, ultrasound-guided costoclavicular approach provides an effective and safe alternative to ultrasound-guided axillary approach of brachial plexus block for below elbow surgeries.

REFERENCES

- [1] Park SK, Lee SY, Kim WH, Park HS, Lim YJ, Bahk JH. Comparison of supraclavicular and infraclavicular brachial plexus block: A systemic review of randomized controlled trials. *Anaesth Analg.* 2017;124(2):636-44. Doi: 10.1213/ANE.0000000000001713. PMID: 27828793.
- [2] Song IA, Gil NS, Choi EY, Sim SE, Min SW, Ro YJ, et al. Axillary approach versus the infraclavicular approach in ultrasound-guided brachial plexus block: Comparison of anaesthetic time. *Korean J Anaesthesiol.* 2011;61(1):12-18. Doi: 10.4097/kjae.2011.61.1.12. Epub 2011 Jul 21. PMID: 21860745; PMCID: PMC3155130.
- [3] Stav A, Reytman L, Stav MY, Portnoy I, Kantarovskiy A, Galili O, et al. Comparison of the supraclavicular, infraclavicular and axillary approaches for ultrasound-guided brachial plexus block for surgical anaesthesia. *Rambam Maimonides Med J.* 2016;7(2):e0013. Doi: 10.5041/RMMJ.10240. PMID: 27101216; PMCID: PMC4839540.
- [4] Sites BD, Beach ML, Spence BC, Wiley CW, Shiffrin J, Hartman GS, et al. Ultrasound guidance improves the success rate of a perivascular axillary plexus block. *Acta Anaesthesiol Scand.* 2006;50(6):678-84. Doi: 10.1111/j.1399-6576.2006.01042.x. PMID: 16987361.

- [5] Li JW, Songthamwat B, Samy W, Sala-Blanch X, Karmakar MK. Ultrasound-guided costoclavicular brachial plexus block: Sonoanatomy, technique, and block dynamics. *Reg Anaesth Pain Med*. 2017;42(2):233-40. Doi: 10.1097/AAP.0000000000000566. PMID: 28157792.
- [6] Arnuntasupakul V, Leurcharusmee P, Chora De La Garza D, Ah-Kye S, Finlayson RJ, et al. A randomized trial comparing axillary block versus targeted intracluster injection supraclavicular block for upper limb surgery. *Can J Anaesth*. 2015;62(12):1287-94. Doi: 10.1007/s12630-015-0485-x. Epub 2015 Oct 2. PMID: 26431854.
- [7] Sala-Blanch X, Reina MA, Pangthipapai P, Karmakar MK. Anatomic basis for brachial plexus block at the costoclavicular space: A cadaver anatomic study. *Reg Anaesth Pain Med*. 2016;41(3):387-91.
- [8] Cesur S, Yayik AM, Daş AN, Ahiskalioglu A. A randomized comparison between ultrasound-guided costoclavicular and infraclavicular block for upper extremity surgery. *Turk J Med Sci*. 2021;51(4):1883-88. Doi: 10.3906/sag-2011-126. PMID: 33890449; PMCID: PMC8569785.
- [9] Xing T, Ge L. Ultrasound-guided brachial plexus block by costoclavicular space approach: A narrative review. *Med Sci Monit*. 2023;29:e939920. Doi: 10.12659/MSM.939920. PMID: 37448107; PMCID: PMC10353486.
- [10] Albrecht E, Mermoud J, Fournier N, Kern C, Kirkham KR. A systematic review of ultrasound-guided methods for brachial plexus blockade. *Anaesthesia*. 2016;71(2):213-27. Doi: 10.1111/anae.13347. Epub 2015 Dec 16. PMID: 26670119.
- [11] Mondal S, Sinha C, Kumari P, Kumar A, Kumar A, Agarwal P. Costoclavicular versus lateral sagittal infraclavicular brachial plexus block for postoperative analgesia in patients undergoing upper limb orthopaedic surgery: A randomised controlled trial. *Indian J Anaesth*. 2024;68(8):693-98. Doi: 10.4103/ija.ija_812_23. Epub 2024 Jul 2. PMID: 39176120; PMCID: PMC11338381.
- [12] Nalini KB, Bevinaguddaiah Y, Thiagarajan B, Shivasankar A, Pujari VS. Ultrasound-guided costoclavicular vs. axillary brachial plexus block: A randomized clinical study. *J Anaesthesiol Clin Pharmacol*. 2021;37(4):655-60. Doi: 10.4103/joacp.JOACP_43_20. Epub 2021 Nov 2. PMID: 35340944; PMCID: PMC8944354.
- [13] Zhang L, Pang R, Zhang L. Comparison of ultrasound-guided costoclavicular and supraclavicular brachial plexus block for upper extremity surgery: A propensity score matched retrospective cohort study. *Ann Palliat Med*. 2021;10(1):454-61. Doi: 10.21037/apm-20-2376.
- [14] Deshpande JP, Patil KN. Evaluation of magnesium as an adjuvant to ropivacaine-induced axillary brachial plexus block: A prospective, randomised, double-blind study. *Indian J Anaesth*. 2020;64(4):310-15. Doi: 10.4103/ija.IJA_833_19.
- [15] Vazin M, Jensen K, Kristensen DL, Hjort M, Tanggaard K, Karmakar MK, et al. Low-volume brachial plexus block providing surgical anaesthesia for distal arm surgery comparing supraclavicular, infraclavicular, and axillary approach: A randomized observer blind trial. *Biomed Res Int*. 2016;2016:7094121. Doi: 10.1155/2016/7094121. Epub 2016 Nov 21. PMID: 27990435; PMCID: PMC5136641.
- [16] Sripriya R, Sivashanmugam T, Rajadurai D, Parthasarathy S. Equal mixture of 2% lidocaine with adrenaline and 0.5% bupivacaine 20 mL provided faster onset of complete conduction blockade during ultrasound-guided supraclavicular brachial plexus block than 20 mL of 0.5% bupivacaine alone: A randomized double-blinded clinical trial. *Reg Anaesth Pain Med*. 2024;49(2):104-09. Doi: 10.1136/rapm-2023-104542. PMID: 37295795.
- [17] Takeda A, Ferraro LH, Rezende AH, Sadatsune EJ, Falcão LF, Tardelli MA. Minimum effective concentration of bupivacaine for axillary brachial plexus block guided by ultrasound. *Braz J Anaesthesiol*. 2015;65(3):163-69. Doi: 10.1016/j.bjane.2013.11.007. Epub 2015 Feb 16. PMID: 25925026.
- [18] Ramesh SM, Janardhaniyengar SM, Kantharaju S. Comparison of ultrasound guided costoclavicular brachial plexus block versus supraclavicular brachial plexus block for forearm and hand surgeries for surgical anaesthesia: A prospective randomised clinical study. *Indian J Clin Anaesth*. 2021;8(1):96-101.
- [19] Leurcharusmee P, Elgueta MF, Tiyaprasertkul W, Sotthisopha T, Samerchua A, Gordon A, et al. A randomized comparison between costoclavicular and paracocoid ultrasound-guided infraclavicular block for upper limb surgery. *Can J Anaesth*. 2017;64(6):617-25. English. Doi: 10.1007/s12630-017-0842-z. Epub 2017 Feb 15. PMID: 28205117.
- [20] Tran DQ, Russo G, Muñoz L, Zaouter C, Finlayson RJ. A prospective, randomized comparison between ultrasound-guided supraclavicular, infraclavicular, and axillary brachial plexus blocks. *Reg Anaesth Pain Med*. 2009;43(4):366-71. Doi: 10.1097/AAP.0b013e3181ac7d18. PMID: 19574871.
- [21] Yanli Y, Ozdemir M, Bakan N. Our experiences with a single injection axillary block technique. *North Clin Istanb*. 2014;1(1):39-44. Doi: 10.14744/nci.2014.02996. PMID: 28058300; PMCID: PMC5175022.
- [22] Songthamwat B, Karmakar MK, Li JW, Samy W, Mok LYH. Ultrasound-guided infraclavicular brachial plexus block: Prospective randomized comparison of the lateral sagittal and costoclavicular approach. *Reg Anaesth Pain Med*. 2018;43(8):825-31.
- [23] Dost B, Kaya C, Ustun YB, Turunc E, Baris S. Lateral sagittal versus costoclavicular approaches for ultrasound-guided infraclavicular brachial plexus block: A comparison of block dynamics through a randomized clinical trial. *Cureus*. 2021;13(3):e14129. Doi: 10.7759/cureus.14129. PMID: 33912361; PMCID: PMC8071096.
- [24] Luo Q, Zheng J, Yang C, Wei W, Wang K, Xiang X, et al. Effects of the costoclavicular block versus interscalene block in patients undergoing arthroscopic shoulder surgery under monitored anaesthesia care: A randomized, prospective, non-inferiority study. *Korean J Anaesthesiol*. 2023;76(5):413-23. Doi: 10.4097/kja.22638.
- [25] Ahuja V, Thapa D, Gombhar S, Dhiman D. To determine block establishment time of supraclavicular brachial plexus block using blunt versus short bevel needle: A prospective randomized trial. *Saudi J Anaesth*. 2016;10(3):259-64. Doi: 10.4103/1658-354X.174910. PMID: 27375378; PMCID: PMC4916807.
- [26] Nijs K, Van Rossum M, Ory JP, Pierson M, De Wachter G, Callebaut I, et al. Ultrasound-guided axillary brachial plexus block versus distal peripheral forearm nerve block for hand and wrist surgery: A randomised controlled trial. *Br J Anaesth*. 2023;131(1):e20-e22. Doi: 10.1016/j.bja.2023.03.020. Epub 2023 Apr 18. PMID: 37080867.
- [27] Hussien R, Ibrahim D. Ultrasound guided axillary brachial plexus block versus supraclavicular block in emergency crushed hand patients: A comparative study. *Open Anaesthesia J*. 2018;12: http://dx.doi.org/10.2174/2589645801812010034.

PARTICULARS OF CONTRIBUTORS:

1. Assistant Professor, Department of Anaesthesia, Chikkaballapura Institute of Medical Sciences, Chikkaballapura, Karnataka, India.
2. Professor, Department of Anaesthesia and Critical Care, St. Johns Medical College, Bangalore, Karnataka, India.
3. Assistant Professor, Department of Anaesthesia and Critical Care, St. Johns Medical College, Bangalore, Karnataka, India.

NAME, ADDRESS, E-MAIL ID OF THE CORRESPONDING AUTHOR:

Thomas T Vellapally,
Assistant Professor, Department of Anaesthesia and Critical Care, St. Johns Medical College, Koramangala, Bangalore-560034, Karnataka, India.
E-mail: tvthomas1985@gmail.com

AUTHOR DECLARATION:

- Financial or Other Competing Interests: None
- Was Ethics Committee Approval obtained for this study? Yes
- Was informed consent obtained from the subjects involved in the study? Yes
- For any images presented appropriate consent has been obtained from the subjects. Yes

PLAGIARISM CHECKING METHODS: [Jain H et al.]

- Plagiarism X-checker: Mar 10, 2025
- Manual Googling: May 17, 2025
- iThenticate Software: May 20, 2025 (21%)

ETYMOLOGY: Author Origin

EMENDATIONS: 6

Date of Submission: Mar 03, 2025

Date of Peer Review: Mar 28, 2025

Date of Acceptance: May 22, 2025

Date of Publishing: Aug 01, 2025